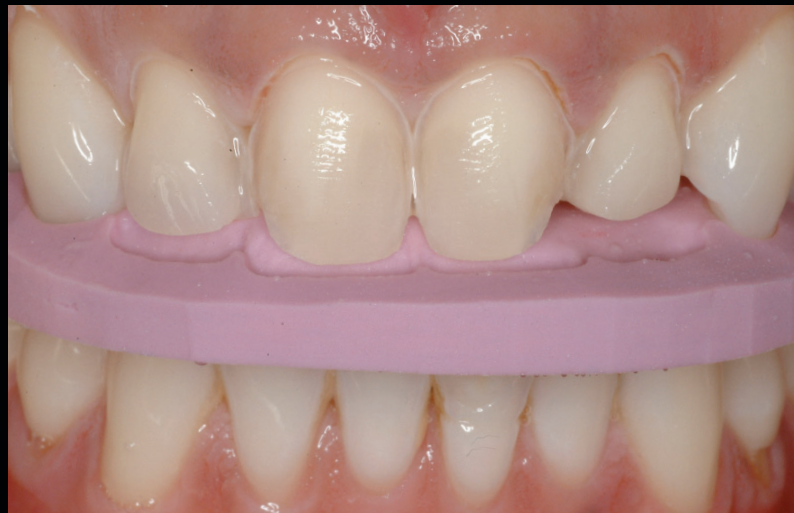

# CONSERVATIVE AESTHETIC ENHANCEMENT OF THE MAXILLARY ANTERIOR USING PORCELAIN LAMINATE VENEERS

Jay M. Lerner, DDS\*



*Dental professionals can use a variety of materials for enhancing the aesthetics of the maxillary dentition. Porcelain laminate veneers have been used for several decades for this expressed purpose; minimally invasive preparation designs and modern ceramic materials make this treatment option increasingly conservative to the natural tooth structures, while providing both predictable and long-lasting aesthetics. This discussion presents the associated clinical considerations and treatment sequences (ie, treatment planning, preparation, provisionalization, cementation) using a series of detailed case presentations.*

#### Learning Objectives:

This article discusses a conservative treatment option when using porcelain laminate veneers. Upon reading this article, the reader should:

- Become familiar with the efficiency of porcelain laminate veneers and how they can be utilized in conservative treatment.
- Understand the benefits of conservative treatment through the cases presented herein.

*Key Words: anterior, conservative, preparation, minimally invasive, porcelain, porcelain laminate veneers (PLVs)*

*\*Senior Clinical Instructor, Rosenthal Institute and Aesthetic Advantage Continuum; private practice, Palm Beach Gardens, FL.*

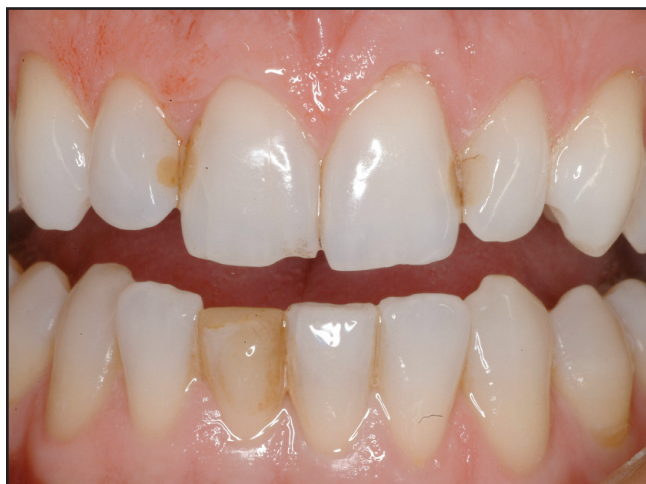*Jay M. Lerner, DDS, 5602 PGA Boulevard, Palm Beach Gardens, FL 33418  
Tel: 561-379-8787 • E-mail: lernerlemongello@aol.com*

## Practical Procedures & AESTHETIC DENTISTRY

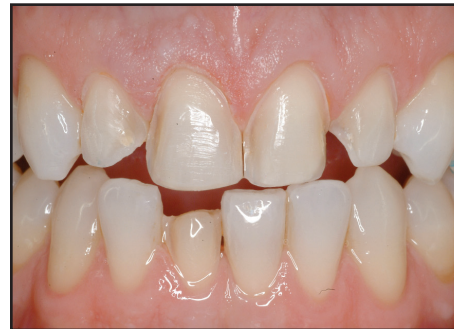Contemporary dental patients have more access to procedural information and treatment alternatives, which empowers them to play a more active role in the planning and execution of restorative care. These consumers have increasing awareness of conservative procedures, and a growing understanding of the impact such techniques can have on the long-term prognosis of their teeth.

One outcome of patients' greater comprehension of dental procedures is an increase in their expectations of the clinician. Because the patient must be pleased with the treatment, a predictable approach should be used to enroll them in the restorative process as soon as feasible. During consultation, it is of utmost importance to discuss the patient's desires, concerns, and limitations, and to discern whether they are emotional, financial, or for another reason. It is essential for the dentist to actively listen to the patient so that a clear understanding of their specific expectations is obtained.<sup>1</sup> From the outset, it is critical that the dentist be able to articulate and create a vision of the anticipated aesthetics for the patient.<sup>1</sup> To avoid any miscommunication and ensure a successful result, there are certain options the dentist has at his or her disposal to demonstrate the appearance of the anticipated outcome prior to treatment. Computer imaging or a composite mock-up has shown to be helpful in demonstrating the appearance of longer teeth or a fuller smile, but the patient also needs to be made aware that it is not until provisional restorations are placed and contoured that the true appearance can be visualized.<sup>2</sup>

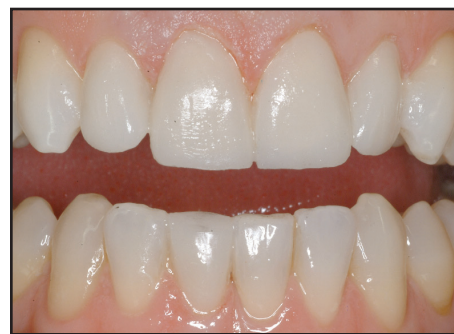Porcelain laminate veneers, by nature a conservative modality that provides excellent potential for aesthetic enhancement when their indications are respected,



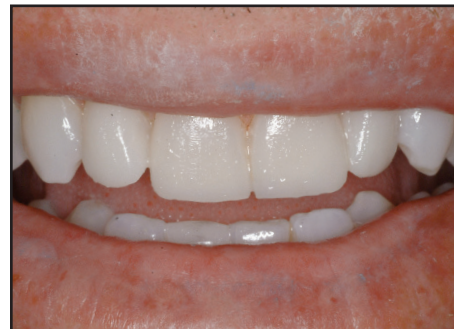**Figure 1. Preoperative view of stained and discolored teeth in the maxilla and mandible.**



**Figure 2. The teeth were prepared by removing the old composite restorations, followed by placement of the interproximal elbow.**

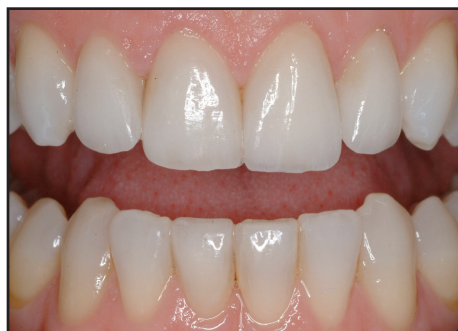

**Figure 3. A retractive view of the maxillary and mandibular anterior provisionals.**

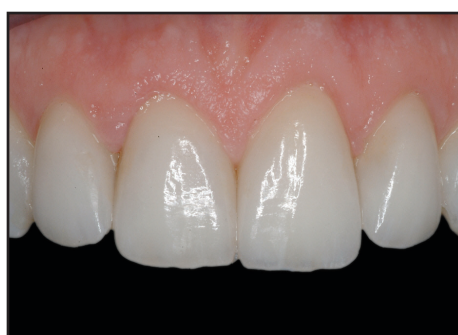

**Figure 4. One of the final steps taken is to do a smile evaluation of provisionals.**

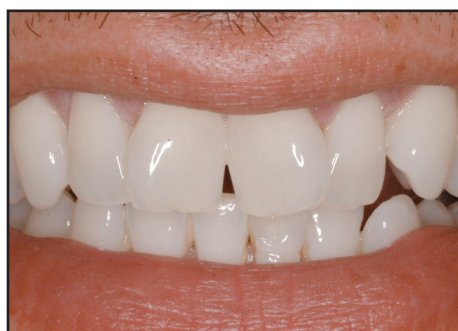can be effective in this regard. Preservation of sound tooth structure must remain a goal throughout tooth preparation.<sup>3</sup> Ideally, this philosophy also entails the clinician's preparation of as few teeth as possible to obtain the desired aesthetics. For example, where the placement of four veneers (potentially with an adjunctive procedure such as tooth whitening) instead of eight or ten could accomplish aesthetic enhancement, the less invasive procedure should be undertaken. Though shade matching can be challenging when one or two teeth are being



**Figure 5.** Retracted view of the final restorations for the maxillary and mandibular anterior teeth.



**Figure 6.** Close up view of the final restorations for the upper maxillary teeth.



**Figure 7.** Preoperative view of the patient's smile reveals misaligned teeth in the anterior maxilla.

treated, veneering the anterior four incisors allows for a more predictable shade match and improved color transition to the posterior teeth. This minimally invasive philosophy should also allow for a more pleasant experience for the patient, while retaining more natural tooth structure.

One of the benefits of the porcelain laminate veneers (PLVs) is predictability. When veneers are selected as the restoration of choice, the clinician and patient can assess the planned outcome of treatment with a great deal of

accuracy. The visualization process starts in the treatment-planning stage and ends with the final refinement of provisional restorations.<sup>2</sup> Additional factors of some importance to the outcome of therapy include a thorough patient consultation, careful material selection, and precise laboratory collaboration.

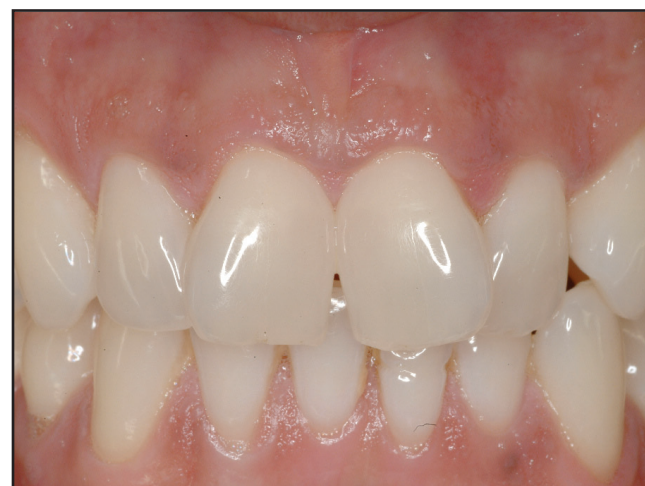This article demonstrates clinical considerations and treatment sequences (ie, treatment planning, preparation, provisionalization, cementation) using a series of detailed case presentations.

## Case Presentations

### Case 1

A 50-year-old male presented with a chief complaint that he disliked the appearance of his discolored "fillings" and the chipped edges of his front teeth (Figure 1). After educating the patient as to the limitations of composite bonding in regards to long-term color stability and strength in a high-stress area (ie, incisal edge repair) and the benefits of a more predictable, longer-lasting solution, namely porcelain veneers, a clinical examination was conducted.

The initial diagnostic evaluation consisted of thorough extra- and intraoral examinations, temporomandibular joint and muscle evaluation, a series of digital photographs, and the mounting of study casts in centric relation. Clinical examination revealed a relatively healthy dentition with adequate oral hygiene. While there was minimal occlusal wear on the posterior teeth, chipping and discolored composite restorations on teeth #7(12) through #10(22) and #25(41) was evident. No joint or muscle tenderness was noted. Upon consultation with the patient, it was decided to take a minimally invasive



**Figure 8.** Retracted preoperative view of the misaligned teeth #7(12) through #10(22).

## Practical Procedures & AESTHETIC DENTISTRY

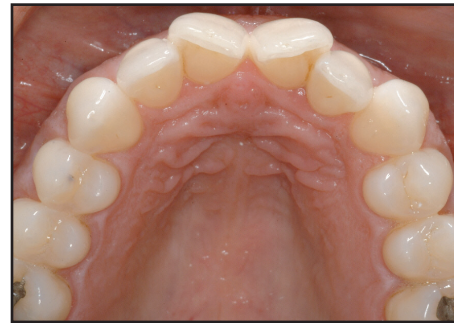
approach to smile design whereby feldspathic porcelain laminate veneers would be placed on the four incisors and tooth #25.

### Preparation

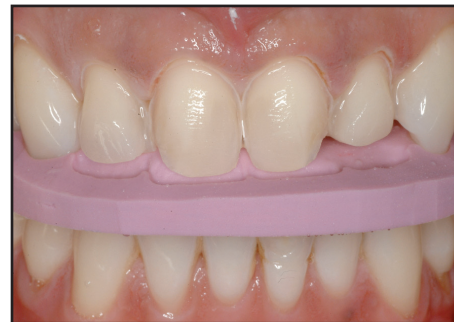Since there was gingival zenith disparity between the central incisors, a diode laser (ie, DiolasePlus, Biolase, Irvine, CA) was used to correct it prior to tooth preparation. Reduction commenced with the establishment of arch form; 0.5-mm depth cuts were subsequently made on all of the teeth. The teeth were prepared as minimally as possible, except for the removal of the old composite restorations (Figure 2), utilizing a diamond bur (ie, #5856-016, Brasseler USA, Savannah, GA) for gross reduction and a round-ended bur (ie, #6844-014, Brasseler USA, Savannah, GA) for the cervical margins and the placement of the interproximal elbow. By preparing the minimal amount (ie, 0.5 mm) of tooth structure needed to achieve the desired results, significant enamel was conserved.

Impressions were then made; also recorded were a face-bow transfer and a bite registration with an inter-pupillary recording stick. These diagnostic criteria would allow the laboratory technician to orient the maxillary model on the articulator (ie, Artex, Jensen Industries, North Haven, CT) and align the incisal edges, thus preventing canting while the definitive restorations were fabricated. The shade of the prepared teeth was then recorded and communicated to the laboratory technician utilizing digital photographs. Slight cervical staining with subtle incisal translucency would also be blended into the final restoration to achieve a polychromatic effect that would complement the existing dentition.

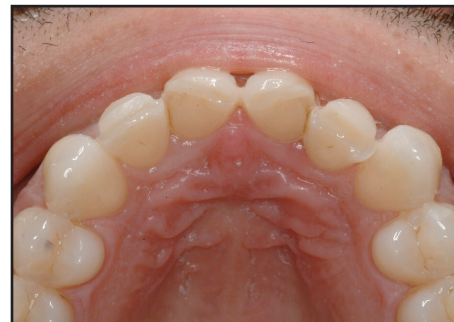Provisionalization was then achieved using a bis-acrylic resin provisional material (ie, Luxatemp Fluorescence, Zenith/DMG, Englewood, NJ) which was placed into a matrix made from a model of the patient's original teeth<sup>4</sup> (Figures 3). Flowable composite (ie, LuxaFlow, Zenith/DMG, Englewood, NJ) was then used to add and recontour the provisional restorations to the appropriate facial contours and incisal length that satisfied aesthetic, phonetic, and functional requirements.<sup>5</sup> When the patient returned two days later, these parameters were then re-evaluated with the lip not anesthetized (Figure 4). Once they were judged satisfactory and the patient approved the provisional restorations, impressions of the provisionals, along with digital photographs, were sent to the ceramist to communicate the length and position of the incisal edges and contours of the definitive restorations.<sup>5</sup>



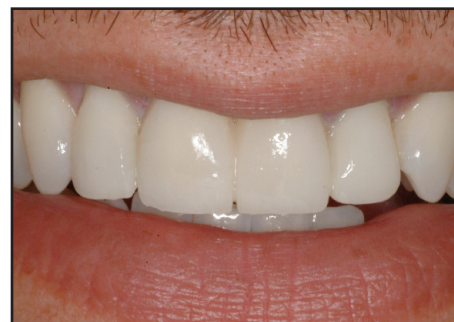**Figure 9.** Preoperative occlusal view taken of the maxillary arch.



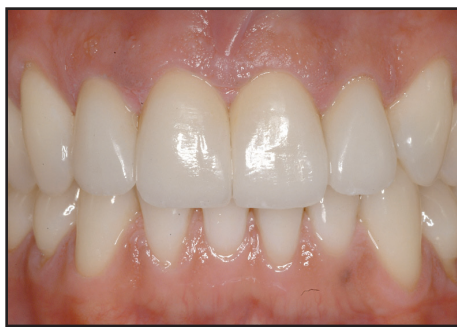**Figure 10.** The teeth were prepared using a laboratory preparation model and an incisal guide index.



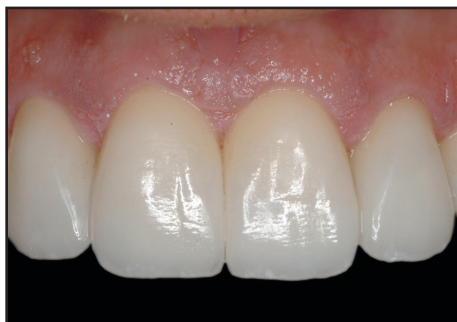**Figure 11.** Occlusal view of the prepared maxillary incisors.



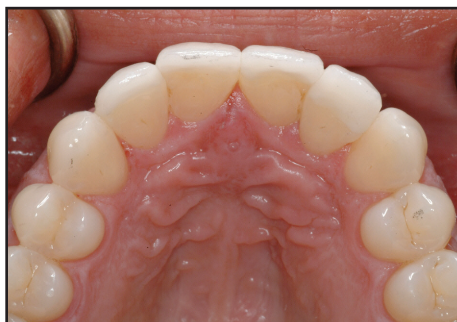**Figure 12.** View of the provisional restorations used to confirm aesthetic improvement of the patient's smile.



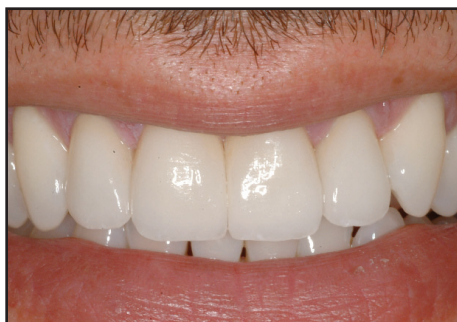**Figure 13.** Retracted view of the final restorations.



**Figure 14.** Close-up view of final restorations of teeth #7(12) through #10(22).



**Figure 15.** Occlusal view of the final restorations on the maxillary incisors.



**Figure 16.** View of the patient's smile demonstrating improved aesthetics.

#### *Seating and Cementation*

When returned from the laboratory, the restorations were evaluated for marginal integrity on the trimmed working die and solid models. Upon removal of the provisionals, the restorations were tried in with water to verify marginal fit and then with try-in gel (ie, Variolink Veneer, Ivoclar Vivadent, Amherst, NY) to evaluate shade and aesthetics. A neutral shade was selected to allow for a chameleon effect of the underlying tooth stump shade and to help increase the vitality and natural appearance of the final veneers. The restorations were then removed and cleaned with 32% phosphoric acid, rinsed, dried, and silanated. The preparations were isolated with a rubber dam and cleaned with Consepsis (Ultradent Products, South Jordan, UT).

According to the total-etch technique,<sup>6,7</sup> the preparations were etched with 32% phosphoric acid for 10 to 15 seconds before being thoroughly rinsed and excess water was removed with a high-speed evacuator. A wetting agent (ie, Gluma Desensitizer, Heraeus Kulzer, Armonk, NY) was applied and gently blotted with a cotton pellet, making sure the dentin stayed moist. A fifth-generation bonding agent (ie, Prime & Bond NT, Dentsply Caulk, Milford, DE) was applied copiously to the preparations and allowed to penetrate the dentin for 20 seconds. The preparations were then lightly air-dried to evaporate the acetone in the bonding agent before being cured with a halogen light for 40 seconds. The restorations were internally coated with the bonding agent but were not cured. A light-cured luting cement (ie, Variolink Veneer, Ivoclar Vivadent, Amherst, NY) which distinguishes shades by value was used to bond the veneers into place. The restorations were then seated together using the rapid cementation technique.<sup>8</sup> Following cleanup of excess cement, the restorations were finished and polished, and occlusion was adjusted for centric contacts and anterior guidance.

The patient returned to the office one week later to permit a final examination of aesthetics, phonetics, and occlusion. He was satisfied with the aesthetic enhancement achieved through this predictable restorative approach (Figures 5 and 6).

#### **Case 2**

A 35-year-old male presented with the chief complaint that he was dissatisfied with the appearance of his teeth. On interview, he related that as a child he was not very cooperative in maintaining his orthodontic braces and removed them prematurely. He also related that finances were a limitation and that he did not have the ability to undergo extensive, costly dentistry.

## Practical Procedures & AESTHETIC DENTISTRY

After an initial comprehensive examination was conducted, as described previously, it was determined that the patient had a fairly healthy dentition except for the misshapen and misaligned maxillary incisors (Figures 7 through 9). He also exhibited areas of posterior abfraction, which was consistent with the patient's history of bruxism and vigorous tooth brushing. After consultation with the patient, taking into account his aesthetic desires and financial limitations, it was decided to achieve an acceptable result by restoring the maxillary incisors with porcelain veneers. The patient was also advised that the mandibular incisors would need to be recontoured in order to establish proper anterior guidance and coupling;<sup>9,10</sup> the author also recommended that he wear a night guard to protect his teeth from further wear. Following a diagnostic workup, which included models mounted in centric relation, a diagnostic waxup was fabricated along with a preparation model and guide.

### Preparation

Following the same preparation guidelines outlined previously, teeth #7 through #10 were prepared with minimal reduction utilizing the laboratory preparation model and incisal guide index (Figure 10). Tooth #10 was prepared slightly more aggressively in order to correct its arch form position (Figure 11). Impressions were made, and a face-bow registration was obtained along with a centric relation bite record. As in case 1, the shade of the patient's remaining dentition was satisfactory, so the ceramist was instructed to match the shade of the veneers to the rest of the dentition.

Provisionalization was achieved and, following the patient's return visit for recontouring, digital photographs and a model of the provisional restorations were forwarded to the ceramist (Figures 12 and 13). Once returned from the laboratory, cementation was achieved utilizing shaded resin cement (ie, Variolink Veneer, Ivoclar Vivadent, Amherst, NY) and the restorations were then finished and polished to their final luster (Figures 14 through 16).

### Guiding the Preparation

A preparation model and guide are very helpful to the dental practitioner, as they allow him or her to visualize the amount of tooth reduction necessary to achieve the desired aesthetic result. Too often, more tooth structure is removed than is necessary in preparation of misaligned teeth, which can result in an increase in tooth sensitivity or a less retentive bond as all the enamel is removed

unnecessarily. The more conservative the tooth preparation, the greater the life expectancy of the veneer restorations. If clinicians follow this philosophy, then eventually when the restorations need to be redone, there will still be enough tooth structure left to replace with new veneers, instead of resorting to full coverage.

### Conclusion

As demonstrated in the aforementioned case presentations, practicing conservative treatment with PLVs can lead to a successful outcome for both the clinician and the patient. When striving to preserve the natural dentition, the techniques outlined will aid the dental practitioner during the decision-making process as well as the restorative procedure itself. Treating the least amount of teeth required to obtain a beautiful, natural smile will be helpful in preventing overtreatment. Efficient treatment provided by a clinician leads to greater patient confidence and trust in their practitioner.

### Acknowledgment

*The author mentions his gratitude to Mr. Peter Kouvaris of JK Dental Laboratory, Great Neck, NY, for the fabrication of the ceramic restorations shown in these cases, and he declares no financial interest in any of the products cited herein.*

### References

1. Smallwood T. Fabricating the undetectable smile: Choose natural over artificial. *J Cosmetic Dent* 2006;22(1):94-103.
2. Mizrahi B. Visualization before finalization: A predictable procedure for porcelain laminate veneers. *Pract Proced Aesthet Dent* 2005;17(8):513-518.
3. Milnar FJ. Mastering minimal intervention and discretionary aesthetic procedures when placing direct composites. *Pract Proced Aesthet Dent* 2005;17(6):428-432.
4. Roberts M, Trinkner T. Communication guidelines for achieving aesthetic success. *Signature* 1998;5(3):18-21.
5. Fondriest JF. Using provisional restorations to improve results in complex aesthetic restorative cases. *Pract Proced Aesthet Dent* 2006;18(4):217-223.
6. Kanca J 3rd. Improving bond strength through acid etching of dentin and bonding to wet dentin surfaces. *J Am Dent Assoc* 1992;123(9):35-43.
7. Kanca J 3rd. Resin bonding to wet substrate. I. Bonding to dentin. *Quintessence Int* 1992;23(1):39-41.
8. Lemongello GJ, Lerner J. Using porcelain veneers with a low-wear ceramic system. *Contemp Esthet* 2000;4(Suppl 2):7-11.
9. Cranham JC. The horizontal position of the maxillary incisal edge: The key to optimum esthetics, phonetics, and function. *Contemp Esthet* 2006;10(2):22-24.
10. Cranham C. Functional considerations in elective esthetic dentistry. *Contemp Esthet* 2005;9(12):38-41.
11. Rosenthal L. Syllabus for aesthetic advantage continuum. Rosenthal Institute of NYU Dental School; April 2006.

# CONTINUING EDUCATION (CE) EXERCISE No. 13



To submit your CE Exercise answers, please use the answer sheet found within the CE Editorial Section of this issue and complete as follows: 1) Identify the article; 2) Place an X in the appropriate box for each question of each exercise; 3) Clip answer sheet from the page and mail it to the CE Department at Montage Media Corporation. For further instructions, please refer to the CE Editorial Section.

The 10 multiple-choice questions for this Continuing Education (CE) exercise are based on the article "Conservative aesthetic enhancement of the maxillary anterior using porcelain laminate veneers," by Jay M. Lerner, DDS. This article is on Pages 361-366.

1. Contemporary dental patients display a higher awareness and more access to what type(s) of information?
  - a. Conservative procedures.
  - b. Long-term impacts of certain techniques.
  - c. The ability to play a more active role in planning.
  - d. All of the above.
2. What should be created to avoid the common problem of more tooth structure being removed than necessary during the procedure?
  - a. An x-ray.
  - b. Preparation model and guide.
  - c. A digital radiograph.
  - d. Nothing, this is not a common problem.
3. What clinical consideration(s) and treatment sequence(s) does this article demonstrate?
  - a. Treatment planning.
  - b. Preparation.
  - c. Provisionalization.
  - d. All of the above.
4. What are the restorations evaluated for when they are first returned from the laboratory?
  - a. Color.
  - b. Size.
  - c. Marginal integrity.
  - d. Width versus height.
5. What type(s) of option(s) does a dentist have at his or her disposal to demonstrate the appearance of the anticipated outcome?
  - a. Computer imaging.
  - b. Composite mock-up.
  - c. Both a and b.
  - d. Neither a nor b.
6. What is important to discuss with the patient at the interview stage?
  - a. Desires.
  - b. Concerns.
  - c. Limitations.
  - d. All of the above.
7. One benefit of the porcelain laminate veneer is its predictability. An additional factor in the importance of its outcome is careful material selection.
  - a. Both statements are true.
  - b. Both statements are false.
  - c. Only the first statement is true.
  - d. Only the second statement is true.
8. Which of the following is a problem that can occur due to too much tooth structure being removed?
  - a. No problems are associated with it.
  - b. Gingivitis.
  - c. Gum bleeding.
  - d. Increased tooth sensitivity.
9. Which of the following is an important factor to the outcome of therapy?
  - a. A thorough patient consultation.
  - b. Careful material selection.
  - c. Precise laboratory collaboration.
  - d. All of the above.
10. Treating the least amount of teeth possible leads to the prevention of which of the following?
  - a. A lower cost to the patient.
  - b. Overtreatment.
  - c. Tooth sensitivity.
  - d. Provisionalization.