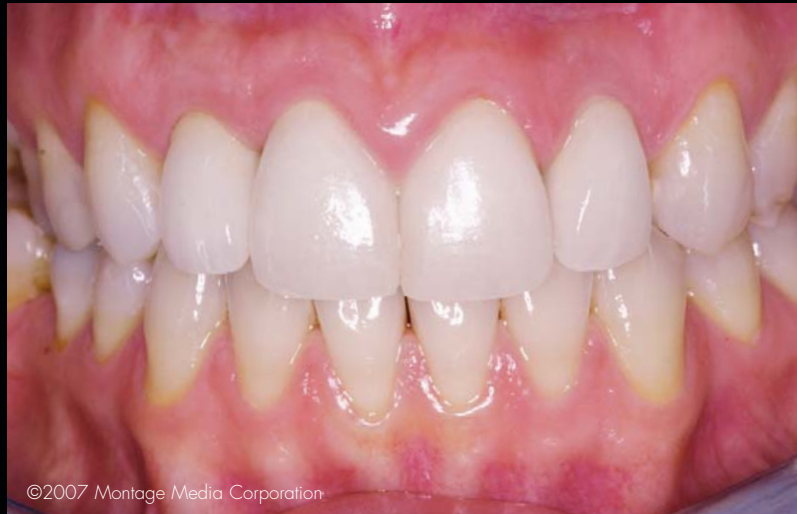

IMMEDIATE CUSTOM IMPLANT PROVISIONALIZATION: A PROSTHETIC TECHNIQUE

Gerard J. Lemongello, Jr, DMD*



Surgical and restorative techniques that can reduce the loss of hard and soft tissues that often accompany implant placement are desirable. The use of a customized provisional restoration will provide a mechanism to assist the clinician in achieving the preservation of hard and soft tissue. This article will explore clinical scenarios in which the fabrication of an immediate, customized provisional abutment and restoration can be utilized to guide tissue healing and improve the aesthetics of implant restorations. This article will focus on the use of a provisional restoration after traditional healing.

Learning Objectives:

This article outlines a provisionalization technique that can be performed after traditional healing of the implant site. Upon reading this article, the reader should:

- Realize that this technique is also effective when immediate implant loading is not possible.
- Become familiar with the benefits of an immediate customized provisional, including duplicating the emergence profile of the extracted tooth.

Key Words: provisional, implant, prosthetic, immediate

**Private practice, Palm Beach Gardens, FL.*

**Gerard J. Lemongello, Jr, DMD, 5602 PGA Blvd., Ste. 201, Palm Beach Gardens, FL 33418
Tel: 561-627-9000 • E-mail: lernerlemongello@aol.com**

Dental implants are routinely utilized to replace missing teeth and have excellent success rates and several advantages over fixed or removable alternatives for tooth replacement.^{1,3} Implant restorations, however, do present the clinician with some challenges, since preserving the desired gingival and osseous architecture can be difficult.⁴ The framework for the development of healthy aesthetic soft tissue is the osseous tissue, and soft tissue contours are dependant on the supporting hard tissue structures. Preservation of the interproximal bone level of adjacent teeth is essential in supporting the interdental papillae.^{2,3}

In order to ensure the most predictable outcome, the following must be properly orchestrated and completed: 1) proper treatment planning; 2) surgical techniques to reduce the loss of hard and soft tissue; 3) placement of the proper flat emergence profile healing cap to prevent tissue pressure; 4) provisionalization with the proper flat emergence profile on the facial to guide soft tissue and reduce pressure on the gingival to reduce the risk of recession; and 5) fabrication of the definitive restoration.⁵ Many patients who face the implant surgical procedure and prolonged healing period might choose a nonsurgical treatment option. This often leads to the placement of a traditional fixed partial denture which, in the presence of natural adjacent teeth, may not necessarily be the patients' best option. Healing and treatment time—with the placement of an immediate customized fixed provisional restoration—could better serve patients' needs if a treatment modality could be provided that would eliminate the extended surgical procedure. Given the option of reduced treatment time, patients will often choose implant restorations over traditional fixed prosthetics. Furthermore, minimizing the duration of treatment and preserving soft and hard tissue structures should be the clinician's goal, and, therefore, surgical and restorative techniques that can reduce the loss of hard and soft tissues are preferred. The use of a customized provisional restoration will provide a mechanism by which preservation of hard and soft tissues can be achieved.⁶

Immediate implant placement has been advocated to preserve alveolar height and width since 1989,⁷⁻¹⁰ and is recommended for its ability to reduce tissue loss following tooth extraction.¹¹⁻¹³ Utilization of a customized provisional abutment and immediate provisionalization allows for the maintenance of gingival and alveolar structures. They provide optimal aesthetics during the healing phase and the benefit of eliminating the use of a removable prosthesis provisional. The fixed, customized provisional

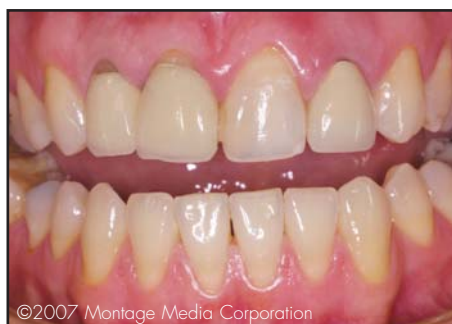

Figure 1. Retracted view of the patient's dentition revealed multiple failing restorations throughout the maxillary and mandibular arches.

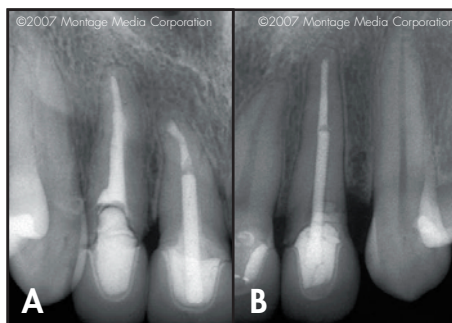


Figure 2A. Preoperative radiograph of the right maxillary anterior regions. **2B.** Periapical radiograph of the left maxilla.

restoration will guide tissue growth during the healing phase.¹⁴ If immediate provisionalization is not possible due to lack of implant stability achieved at the time of surgery or the need for guided bone regeneration at the time of placement, the use of a removable provisional prosthesis may be necessary during the initial healing phase. A properly constructed removable provisional prosthesis can also be used as a transitional appliance to guide soft tissue during healing. Once initial healing is complete, fabrication of the customized provisional abutment and restoration can be performed with great success. When it heals, the tissue can be sculpted and the customized provisional abutment and restoration can be fabricated to support the resulting tissue position.

A predictable aesthetic final restoration is the goal of implant placement, and maintaining the hard and soft tissues is critical to achieving this result.^{9,15} Accordingly, immediate provisionalization provides a number of clinical and patient benefits. Reduced chairtime, elimination of additional surgery, immediate nonocclusal loading, bone preservation, and aesthetic benefits are achieved when the patient receives a customized provisional

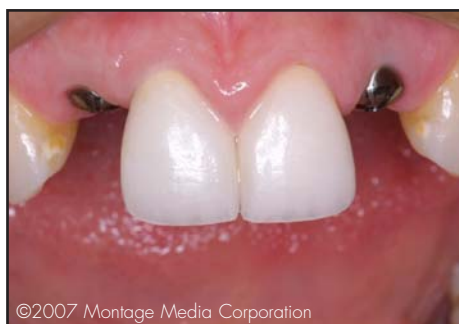

Figure 3. The patient presented with the second-stage healing caps in place approximately six months following implant placement.

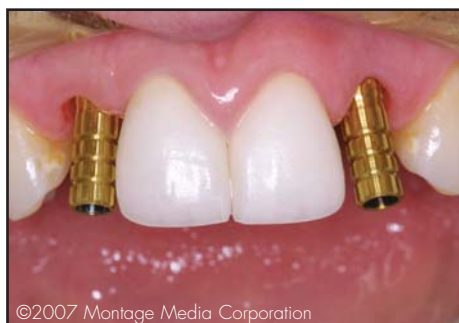

Figure 4. The healing caps were removed, and provisional abutments were placed in site #7 and #10.

restoration on the day of implant surgery. The provisional can be placed at the surgical appointment or the patient can return for it within 24 to 72 hours after surgery. The patient benefits from the immediate aesthetic result that eliminates the need for other forms of removable provisionalization. There are two types of provisionals: 1) laboratory fabricated—whether computer guided or traditionally fabricated with stone and lab components—or 2) custom-fabricated by the clinician. Although a laboratory-fabricated provisional is a viable treatment modality, a provisional restoration customized chairside provides added flexibility in tissue guidance and eliminates additional laboratory expenses. Prefabricated laboratory provisionals, although well planned, may not address the tissue requirements presented chairside. Working with stone models in the laboratory environment, although a good simulation, may not be as accurate as what can be fabricated chairside due to tissue changes encountered as a result of surgery not captured in the pre-treatment stone model.

The position of the implant has to be predetermined with information that is derived from the diagnostic phase

of treatment. This must include study models, radiographs, and clinical findings, which are determined during patient examination. Once this information is gathered, a diagnostic waxup can be created to aid in the fabrication of the necessary surgical guide and provisional matrix, which will guide the fabrication of the provisional restoration. The surgical template will be used at the time of surgery while the provisional matrix will be used to guide the fabrication of the provisional chairside.

A principal benefit of an immediate customized provisional restoration includes duplication of the emergence profile of the extracted tooth.⁴ This allows the gingival embrasure form to be supported while maintaining soft tissue contour and guiding tissue healing. Recreating the interproximal papilla following extraction and implant surgery is difficult. The key to maintaining the interproximal papillae is to preserve the gingival embrasure form at the time of surgery.² Proper soft tissue guidance and support is necessary in the development of natural soft tissue contours and support of the interproximal papillae.

The immediate customized provisional technique also addresses the placement of the restorative margin. With the utilization of cement-retained implant restorations, the clinician creates the restorative margin position at the time of surgery and ensures a predictable tissue position for the definitive restoration. Using a long-term provisional restoration for several weeks may be a prudent way to guide soft tissue dimensions and marginal predictability.

The customized provisional technique is utilized primarily in two clinical treatment scenarios. The ideal situation for its use is immediately following surgical implant placement and immediate implant loading. This technique is equally effective when the surgeon determines that immediate implant loading is not possible due to the surgical limitations or when implant stability is not achieved and requires additional surgical procedures or extended healing time. In this situation, the customized implant procedure can be performed after traditional healing time has occurred with equal effectiveness. The case presented herein will demonstrate how to use this technique in the appropriate situations.

Case Presentation

A 24-year-old healthy female patient presented with multiple failing restorations throughout the maxillary and mandibular arches (Figure 1). Teeth #7(12) and #10(22) had existing crowns with recurrent decay. Both teeth were

structurally compromised with large, oversized endodontic posts. A comprehensive examination was performed and treatment options were presented (Figure 2). Due to financial and time constraints, minimal treatment was requested. The treatment plan consisted of implant placement utilizing customized abutments for teeth #7 and #10, all-ceramic crowns for teeth #8(11) and #9(21), and whitening of the remaining anterior dentition. The patient also understood that additional treatment in the future would be necessary to restore her dentition to proper health.

To preserve bone during integration, platform switching¹⁶ was used with internal connection implants (eg, Osseotite Certain, Implant Innovations, Inc., Palm Beach Gardens, FL) to shift the microgap medially from the periphery. A diagnostic workup, including mounted models, was performed. From the mounted models, a surgical guide was fabricated to aid in surgical placement. A diagnostic waxup of teeth #7 through #10 was created, and a putty matrix was used to facilitate chair-side fabrication of the customized provisional abutment and restoration. An attempt was made to proceed with tooth extraction, immediate implant placement, and immediate placement of a customized provisional abutment and restoration. An aesthetic provisional removable prosthesis was fabricated from the diagnostic waxup in case immediate placement of the provisional was not possible due to implant instability.

Since implant stability was not achieved at the time of surgery, the removable provisional restoration was adjusted and inserted so as to not traumatize the surgical site. A traditional six-month healing period allowed for osseointegration of the implants.¹⁷⁻¹⁹ Based on the expected definitive restorations' proportions and color,

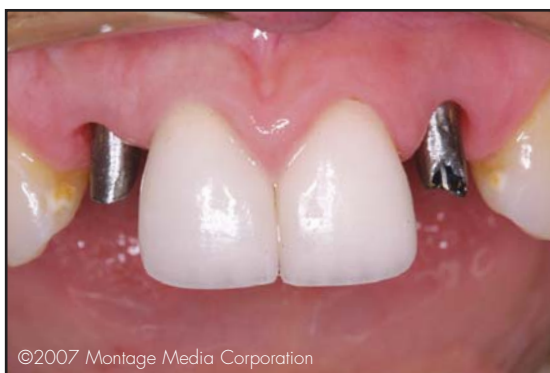

Figure 5. The provisional abutments were prepared to reflect the preparation design required for full coverage of the lateral incisors.

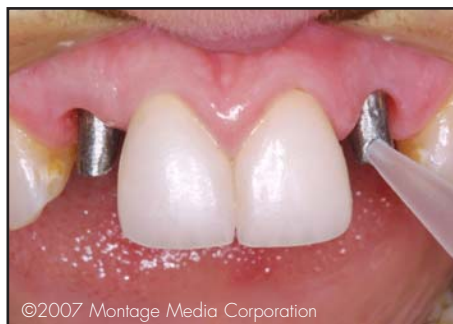

Figure 6. Facial view depicts injection of the provisional material around the prepared provisional abutments.

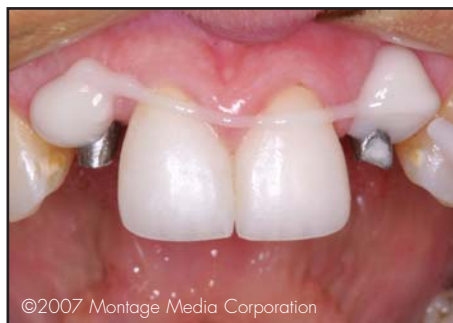

Figure 7. The provisional abutments were covered with a provisional acrylic material, prior to insertion of the putty matrix.

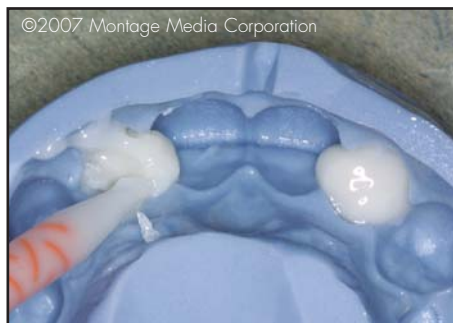

Figure 8. Injection of the provisional material into the putty matrix fabricated from the diagnostic waxup.

the removable provisional prosthesis was created from the diagnostic waxup. Following six weeks of initial primary tissue healing of the surgical site, teeth #8 and #9 were treated with minor laser gingival recontouring to establish soft tissue contour and zenith placement, and the all-ceramic crowns were placed. With the definitive restorations in place, a significant aesthetic improvement was achieved during the remaining five-month healing period and allowed the patient to preview the projected aesthetic outcome. After osseointegration and

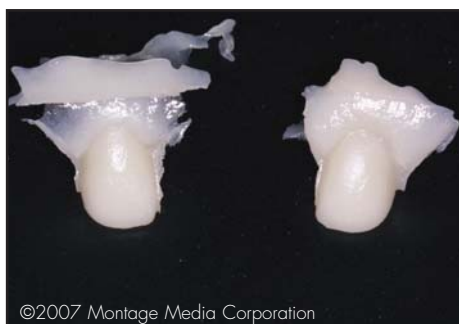

Figure 9. The provisional abutments and restorations were removed from the matrix to facilitate contouring and finishing.

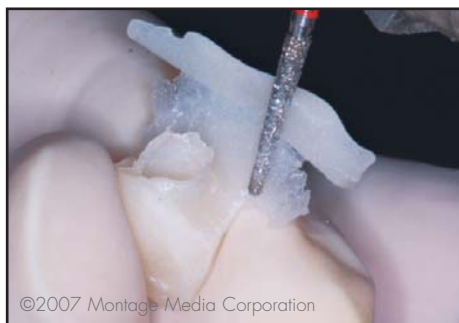

Figure 10. Light-cured composite was used to contour the provisional restoration.



Figure 11. Material was added to the neck of the abutment, which was adjusted until the desired contours were achieved.

second-stage surgery was completed, the patient presented for the final implant-supported restoration of teeth #7 and #10.

Clinical Technique

The patient presented with the second-stage healing screws in place (Figure 3). At this stage, the goal was to fabricate the customized provisional abutment and restoration. Once placed, the clinician could initiate fabrication of the definitive restorations. The purpose of

the customized provisional abutment and restoration was to create the final tissue contours and emergence profile for the definitive restorations. Once created, an impression of the properly formed tissue contours was captured in the final impression, communicated to the dental laboratory, and reproduced in the all-ceramic restorations. Without the customized abutment, the final impression would simply capture the incorrect circular emergence profile of the surgical healing screws.

The healing screws were removed, and provisional abutments were placed to assess the alterations required to achieve appropriate tissue contour, support, and emergence profile (Figure 4). The provisional abutment was then prepared with a high-speed handpiece and significant water coolant to prevent any thermal transfer to the implants (Figure 5). Block-out material was placed in each of the screw access openings so the provisional material would not flow into them. Provisional resin material (ie, Luxatemp, Zenith/DMG, Englewood, NJ) was then injected around the prepared provisional abutments (Figures 6 and 7). The putty matrix, fabricated from the diagnostic waxup, was then filled with this material and seated intraorally (Figure 8). The matrix was then removed after initial curing of the acrylic material; the provisional abutment and restoration were removed to prepare for custom alteration and finishing (Figure 9).

The provisional restoration was contoured with light-cured composite, which was placed around the abutment side of the provisional restorations (Figure 10). This process was repeated as each was contoured to create the proper emergence profile. Composite material was similarly added to the neck of each provisional abutment and contoured until the desired contours had been achieved for the provisional abutment and restorations (Figure 11).

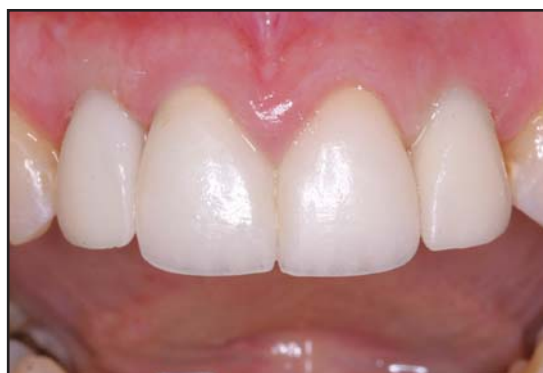

Figure 12. The provisional restorations were cemented in place, and any required occlusal adjustments were made.



Figure 13. Upon receipt from the laboratory, the definitive abutments and crowns were inspected for accuracy.

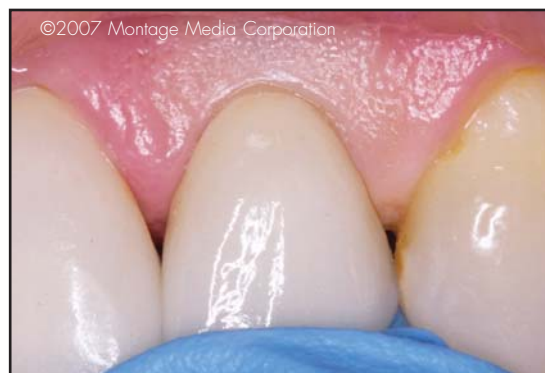

Figure 14. The custom implant abutments and restorations were tried in to ensure accurate fit and aesthetics.

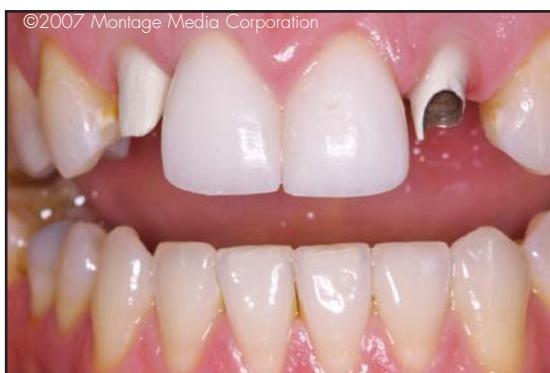

Figure 15. Following successful try-in, a polyvinyl block-out material was placed in the screw access opening.

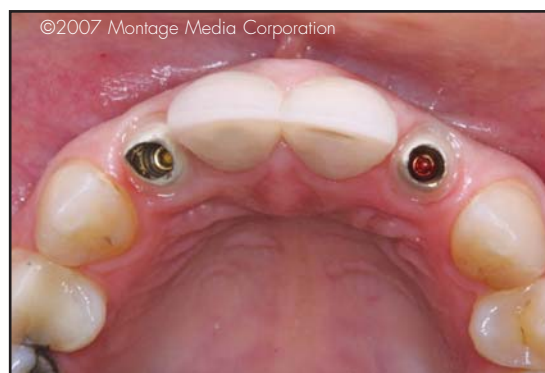

Figure 16. Occlusal view of the final custom abutments seated in proper position for ideal aesthetics and function.

The provisional abutment and restoration were subsequently tried in, and any final adjustments were made for tissue support and emergence profile. The provisional abutment screw was placed and tightened to the proper torque, the provisional restorations were cemented, and the occlusion was adjusted (Figure 12).

Two weeks later, the patient was reappointed for final impression making once the tissue contours were stable. The provisional abutments and restorations were removed, and a conventional final implant impression was taken. The provisional and provisional abutments were replaced as before, and the patient was reappointed for placement of the definitive restorations. A laboratory prescription was completed and the final impression, bite registration, facebow transfer, models of the provisional restorations, and photographs were forwarded to the laboratory. The laboratory technician was instructed to fabricate custom metal abutments and all-ceramic crowns (Figure 13).

At the final appointment, the provisional abutments and restorations were removed, and the customized

implant abutments and crowns were tried in (Figure 14). Once accuracy was verified, the final implant abutment screws were torqued to place. Polyvinyl block-out material was placed in the screw access openings, and the crowns were then cemented with dual-cure composite cement (Figures 15 through 18).

Discussion

While ceramic abutments can be used as the components for the definitive implant restorations, many of the abutments currently available do not allow for the custom subgingival contour of the ceramic. Instead, similar to the surgical healing abutments, they provide a circular rather than an anatomical emergence profile. In the author's opinion, ceramic abutments may become compromised when extensive thinning of the ceramic is necessary, which may reduce the strength of the abutment. Further investigation may be necessary to establish ceramic abutment strength when extensive thinning of ceramic abutments is required, such as with maxillary lateral and mandibular incisors. Alternately, custom-cast

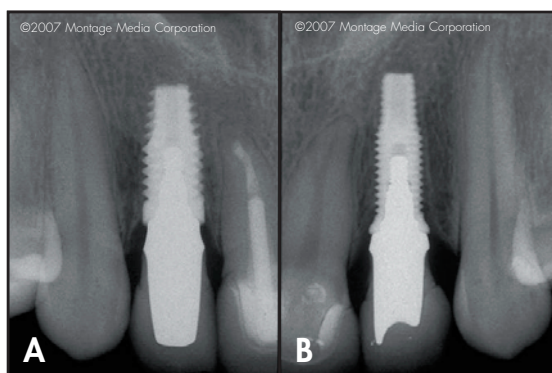


Figure 17A. Postoperative view of implant in site #7. **17B.** Periapical view confirming implant placement in site #10.

metal abutments maintain their strength following preparation and can be opaqued; a ceramic shoulder can be created to mimic the subgingival contour created by the provisional abutment. The ceramic shoulder should extend 0.5 mm subgingival to the free gingival margin.

Conclusion

The utilization of a custom-fabricated provisional abutment and restoration following a six-month period of implant healing can aid in the preservation of hard and soft tissues. In this case, the fabrication of an immediate, customized

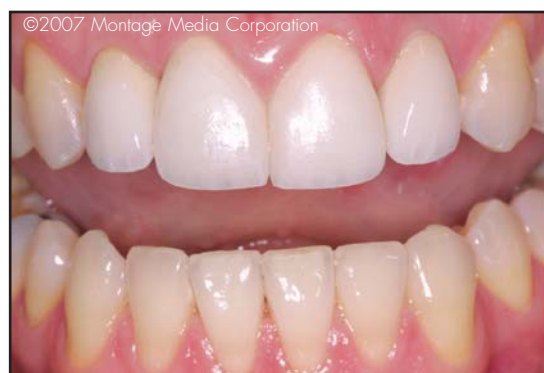

Figure 18. Postoperative view of the definitive implant restorations, all-ceramic crowns, and tooth-whitened anterior dentition.

provisional abutment and restoration was utilized by the author to guide tissue contour and improve implant restorative aesthetics. While beyond the scope of the present article, this provisionalization technique can also be used in conjunction with immediate implant placement.

Acknowledgment

The author declares no financial interest in any of the products mentioned herein. The author mentions his gratitude to Dr. Robert Holt for his expertise in implant placement and Mr. Peter Kouvaras for the aesthetic result in the case herein.

References

1. Kan JYK, Rungcharassaeng K. Immediate placement and provisionalization of maxillary anterior single implants: A surgical and prosthetic rationale. *Pract Periodont Aesthet Dent* 2000; 12(9):817-824.
2. Spear FM. Maintenance of the interdental papilla following anterior tooth removal. *Pract Periodont Aesthet Dent* 1999; 11(1): 21-28.
3. Tarnow DP, Magner AV, Fletcher P. The effect of the distance from the contact point to the crest of the bone on the presence or absence of the interproximal dental papilla. *J Periodontol* 1992; 63(12):995-996.
4. Touati B, Guez G, Saadoun A. Aesthetic soft tissue integration and optimized emergence profile: Provisionalization and customized impression coping. *Pract Periodont Aesthet Dent* 1999; 11(3):305-314.
5. Miller RB. Immediate placement, conventional provisionalization, state-of-the-art aesthetics. *Pract Proced Aesthet Dent* 2006; 18(10 Suppl):13-14.
6. Wöhrlé PS. Single-tooth replacement in the aesthetic zone with immediate provisionalization: Fourteen consecutive case reports. *Pract Periodont Aesthet Dent* 1998; 10(9):1107-1114.
7. Lazzara RJ. Immediate implant placement into extraction sites: Surgical and restorative advantages. *Int J Periodont Rest Dent* 1989; 9(5):333-343.
8. Schropp I, Kostopoulos I, Wenzel A. Bone healing following immediate versus delayed placement of titanium implants into extraction sockets. A prospective clinical study. *Int J Oral Maxillofac Impl* 2003; 18(2):189-199.
9. Schnitman PA, Wöhrlé PS, Rubenstein JE, et al. Ten-year results for Branemark implants immediately loaded with fixed prostheses at implant placement. *Int J Oral Maxillofac Impl* 1997; 12(4):495-503.
10. Morton D, Jaffin R, Weber HP. Immediate restoration and loading of dental implants: Clinical considerations and protocols. *Int J Oral Maxillofac Implants* 2004; 19 Suppl:103-108.
11. Rosenquist B, Grenthe B. Immediate placement of implants into extraction sockets: Implant survival. *Int J Oral Maxillofac Impl* 1996; 11(2):205-209.
12. Pecora G, Andreana S, Covani U, et al. New direction in surgical endodontics: Immediate implantation into an extraction socket. *J Endodont* 1996; 22(3):135-139.
13. Schwartz-Arad D, Chaushu G. The ways and wherefores of immediate placement of implants into fresh extraction sites. A literature review. *J Periodontol* 1997; 68(10):915-923.
14. del Castillo RA. Immediate provisionalization of a single-tooth implant with a temporary cylinder in one surgical appointment. *Pract Proced Aesthet Dent* 2006; 18(5) (suppl):3-5.
15. Kois JC, Kan JY. Predictable peri-implant gingival aesthetics: Surgical and prosthodontic rationales. *Pract Proced Aesthet Dent* 2001; 13(9):691-698.
16. Baumgarten H, Cocchetto R, Testori T, et al. A new implant design for crestal bone preservation: Initial observations and case report. *Pract Proced Aesthet Dent* 2005; 17(10):735-740.
17. Anderson B, Odman P, Lindvall AM, Lithmer B. Single-tooth restorations supported by osseointegrated implants: Results and experiences from a prospective study after 2 to 3 years. *Int J Oral Maxillofac Impl* 1995; 10(6):702-711.
18. Avivi-Arber L, Zarb GA. Clinical effectiveness of implant-supported single-tooth replacement: The Toronto study. *Int J Oral Maxillofac Impl* 1996; 11(3):311-321.
19. Brånemark PI. Osseointegration and its experimental background. *J Prosthet Dent* 1983; 50(3):399-410.